



PRESENTING CLINICAL SIGNS

History: Grade II/VI murmur.

DATE

1/24/23

ECHOCARDIOGRAPHIC FINDINGS

2D, M-mode, and Doppler study.

PERFORMED BY:

Shari Reffi, CVT

INTERPRETED BY

Keith Blass, DVM,
MS, DACVIM
(Cardiology)

Left atrial size is normal. The mitral valve is normal. Left ventricular dimensions are normal. Left ventricular systolic function is hyperdynamic. The aorta and aortic valve are normal. Right atrial and right ventricular dimensions are normal. The tricuspid is normal. The pulmonary artery and pulmonic valve are normal. No heartworms are visualized. There is shunting of blood from the left ventricle to the right ventricle though a defect in the perimembranous interventricular septum. The velocity of the shunting flow is consistent with the presence of a restrictive defect. No pericardial effusion or cardiac masses are seen.

PATIENT

Dixxon Bird

LA - 16.1 mm
LVIDd - 16.2 mm
LVIDs - 8.7 mm
FS - 46%
RA - 12.1 mm
LVOT - 1.00 m/s
RVOT - 0.75 m/s
VSD - 4.73 m/s

SPECIES

Canine

ASSESSMENT/RECOMMENDATIONS

Ventricular septal defect (VSD)

This examination demonstrates the presence of a left-to-right shunting perimembranous VSD. The velocity of the shunting flow is consistent with the presence of a small, restrictive defect, which appears to be supported by the absence of secondary left heart chamber dilation.

BREED

French Bulldog

Restrictive VSDs typically result in minimal left-sided cardiac volume overload and, therefore, typically confer a good long-term prognosis, though careful monitoring for the progressive cardiac volume overload is recommended going forward.

SEX

M

No therapy is recommended at this stage of disease.

A recheck echocardiogram is recommended in ~6 months to monitor for disease progression.

AGE

11 wk

WEIGHT

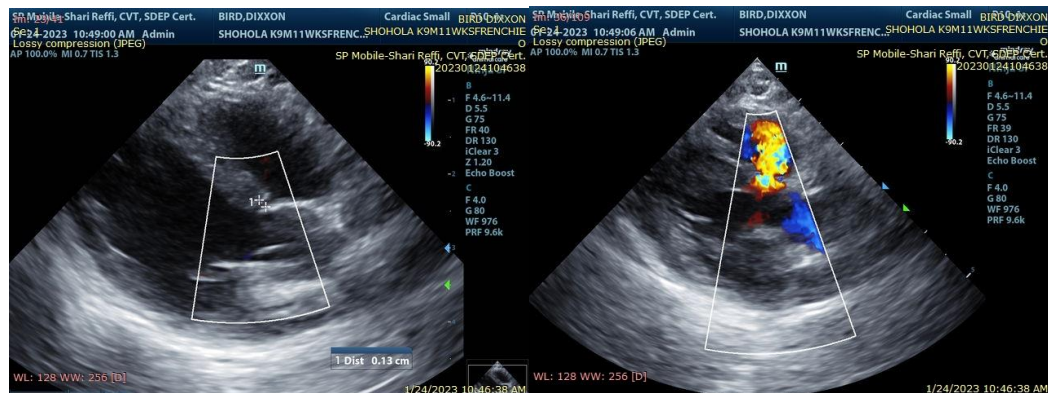
4.1 lb

HOSPITAL NAME

Shohola VH

REFERRING VET

Dr. Gramazio





The information and recommendations provided are based on the images presented by the referring veterinarian. No evaluation can be communicated regarding pathology that was not visible in the image/video clips provided.

DATE

1/24/23

Thank you for this referral. If the clinical or image interpretation does not parallel your findings or if I can be of any further assistance please contact me.

PERFORMED BY:

Shari Reffi, CVT

Keith Blass, DVM, MS, DACVIM (Cardiology)
KeithBlass@gmail.com
631-804-5754

INTERPRETED BY

Keith Blass, DVM,
MS, DACVIM
(Cardiology)

PATIENT

Dixxon Bird

SPECIES

Canine

BREED

French Bulldog

SEX

M

AGE

11 wk

WEIGHT

4.1 lb

HOSPITAL NAME

Shohola VH

REFERRING VET

Dr. Gramazio